


The esophagus

د. محمد محمود حبش

Surgical anatomy

The oesophagus is a muscular tube, approximately **25** cm long, mainly occupying the posterior mediastinum and extending from the upper oesophageal sphincter (the cricopharyngeus muscle) in the neck to the junction with the cardia of the stomach. *It is lined throughout with squamous epithelium.*



The upper sphincter consists of powerful striated muscle. The lower sphincter is more subtle, and is created by the asymmetrical arrangement of muscle fibres in the distal oesophageal wall just above the oesophagogastric junction.

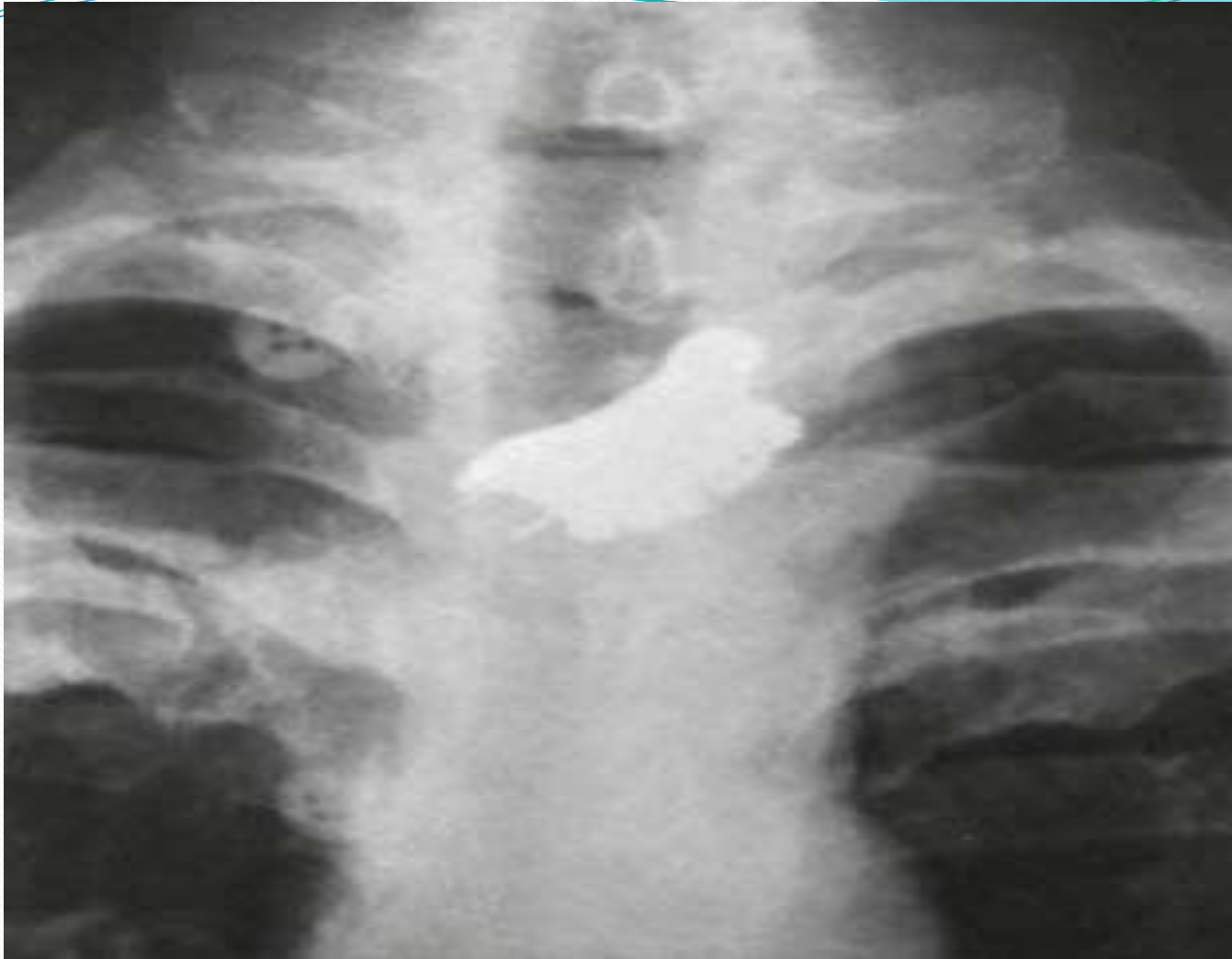

Investigations

Radiography

Contrast radiography has been somewhat overshadowed by endoscopy but remains a useful investigation for demonstrating *narrowing, space-occupying lesions, anatomical distortion or abnormal motility*.

Plain radiographs will show some foreign bodies.



False teeth impacted in the oesophagus

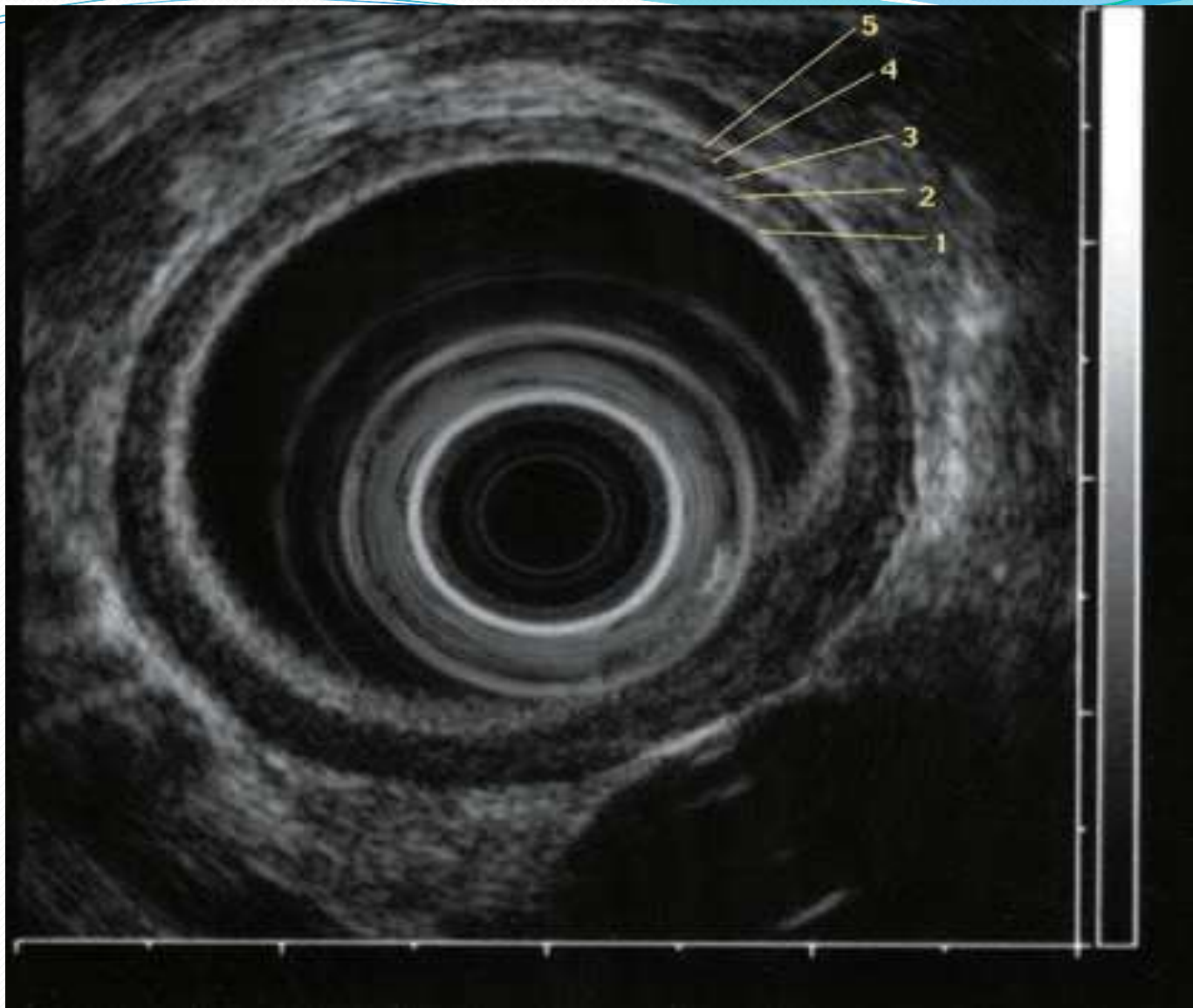
Endoscopy

Endoscopy is necessary for the investigation of most oesophageal conditions. It is required to view the inside of the oesophagus and the oesophagogastric junction, to obtain a biopsy or cytology specimen, for the removal of foreign bodies and to dilate strictures.

Traditionally, there are two types of instrument available, the rigid oesophagoscope and the flexible video endoscope, but the rigid instrument is now virtually obsolete.

Endosonography

Endoscopic ultrasonography relies on a high-frequency (5–30 MHz) transducer located at the tip of the endoscope to provide highly detailed images of the layers of the oesophageal wall and mediastinal structures close to the oesophagus.



Oesophageal manometry

Manometry is now widely used to diagnose oesophageal motility disorders. Recordings are usually made by passing a multilumen catheter with three to eight recording orifices at different levels down the oesophagus and into the stomach. to measure the length and pressure of the LOS and assess motility in the body of the oesophagus during swallowing.

Twenty-four hour pH and combined pH-impedance recording

Prolonged measurement of pH is now accepted as the most accurate method for the diagnosis of gastro-oesophageal reflux. It is particularly useful in patients with atypical reflux symptoms, those without endoscopic oesophagitis and when patients respond poorly to intensive medical therapy.



Perforation of the oesophagus

PERFORATION

Perforation of the oesophagus is usually iatrogenic (at therapeutic endoscopy) or due to 'barotrauma' (spontaneous perforation).

Many instrumental perforations can be managed conservatively, but spontaneous perforation is often a life threatening condition that regularly requires surgical intervention.

Barotrauma (spontaneous perforation, Boerhaave syndrome)

This occurs classically when a person vomits against a closed glottis. The pressure in the oesophagus increases rapidly, and the oesophagus bursts at its weakest point in the lower third, sending a stream of material into the mediastinum and often the pleural cavity as well. *Boerhaave syndrome* is the most serious type of perforation because of the large volume of material that is released under pressure.

Pathological perforation

Free perforation of ulcers or tumours of the oesophagus into the pleural space is rare. Erosion into an adjacent structure with fistula formation is more common. Aerodigestive fistula is most common and usually encountered in primary malignant disease of the oesophagus or bronchus.

Penetrating injury

Perforation by knives and bullets is uncommon, even in war, as the oesophagus is a relatively small target surrounded by other vital organs.

Foreign bodies

The oesophagus may be perforated during removal of a foreign body but, occasionally, an object that has been left in the oesophagus for several days will erode through the wall.



Instrumental perforation

Instrumentation is by far the most common cause of perforation. Modern instrumentation is remarkably safe, but perforation remains a risk that should never be forgotten.

Treatment of oesophageal perforations

General guidelines for non-operative management include:

The principles of non-interventional management

Involve

hyperalimentation, preferably by an enteral route, nasogastric suction and

broad-spectrum intravenous antibiotics.

Surgical management is required whenever patients:

- are unstable with sepsis or shock;
- have evidence of a heavily contaminated mediastinum, pleural space or peritoneum;
- have widespread intrapleural or intraperitoneal extravasation of contrast material.

Factors that favour non-operative management

Small septic load

Minimal cardiovascular upset

Perforation confined to mediastinum

Perforation by flexible endoscope

Perforation of cervical oesophagus

Factors that favour operative repair

Large septic load

Septic shock

Pleura breached

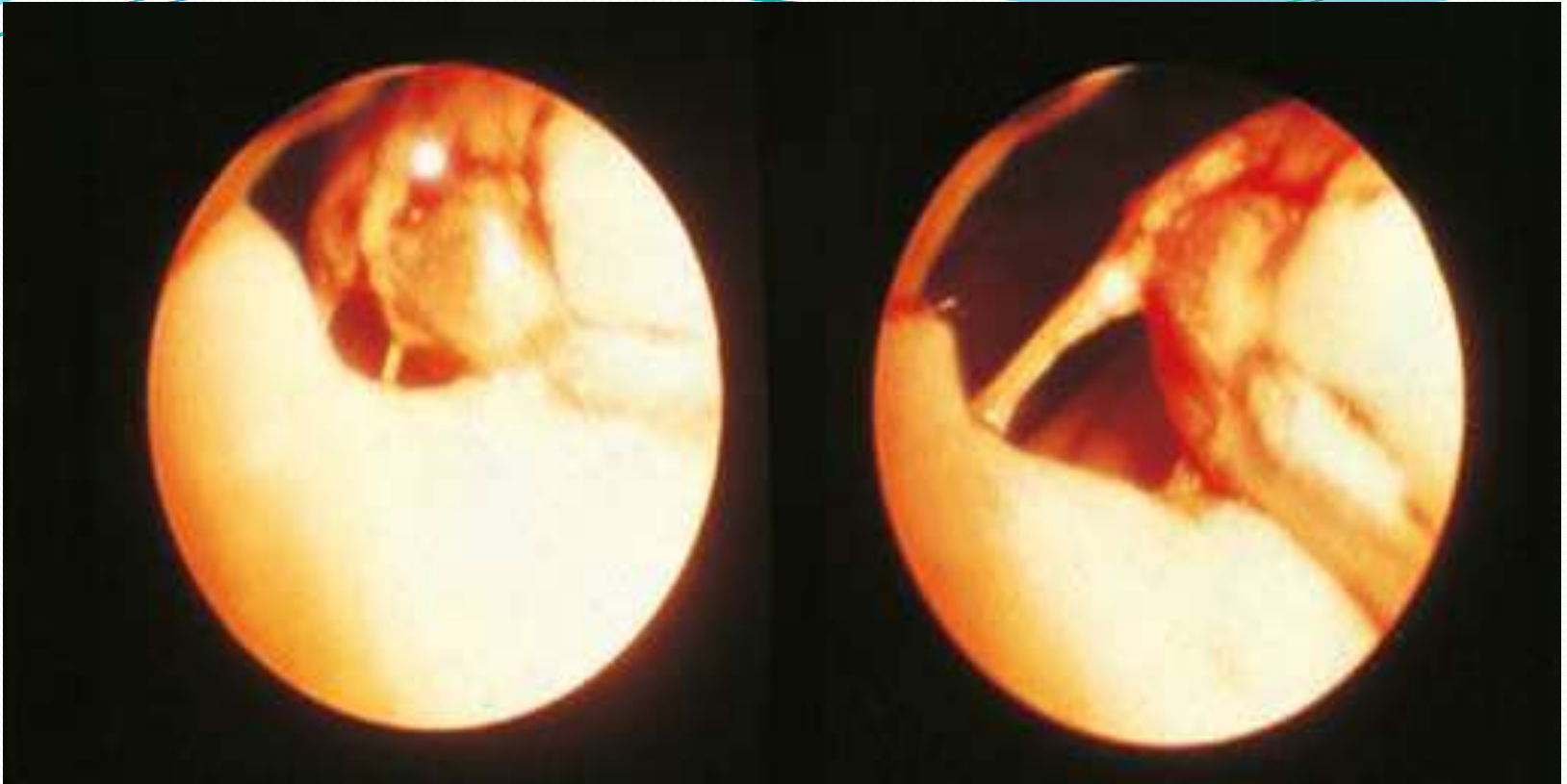
Boerhaave's syndrome

Perforation of abdominal oesophagus

MALLORY-WEISS SYNDROME

Forceful vomiting may produce a mucosal tear at the cardia rather than a full perforation. In Mallory- Weiss syndrome, vigorous vomiting produces a vertical split in the gastric mucosa, immediately below the squamocolumnar junction at the cardia in 90 per cent of cases. In only 10 per cent is the tear in the oesophagus. *The condition presents with haematemesis.*

Usually, the bleeding is not severe, but endoscopic injection therapy may be required for the occasional, severe case. Surgery is rarely required.



The endoscopic appearance of a mucosal tear at the cardia (Mallory-Weiss)

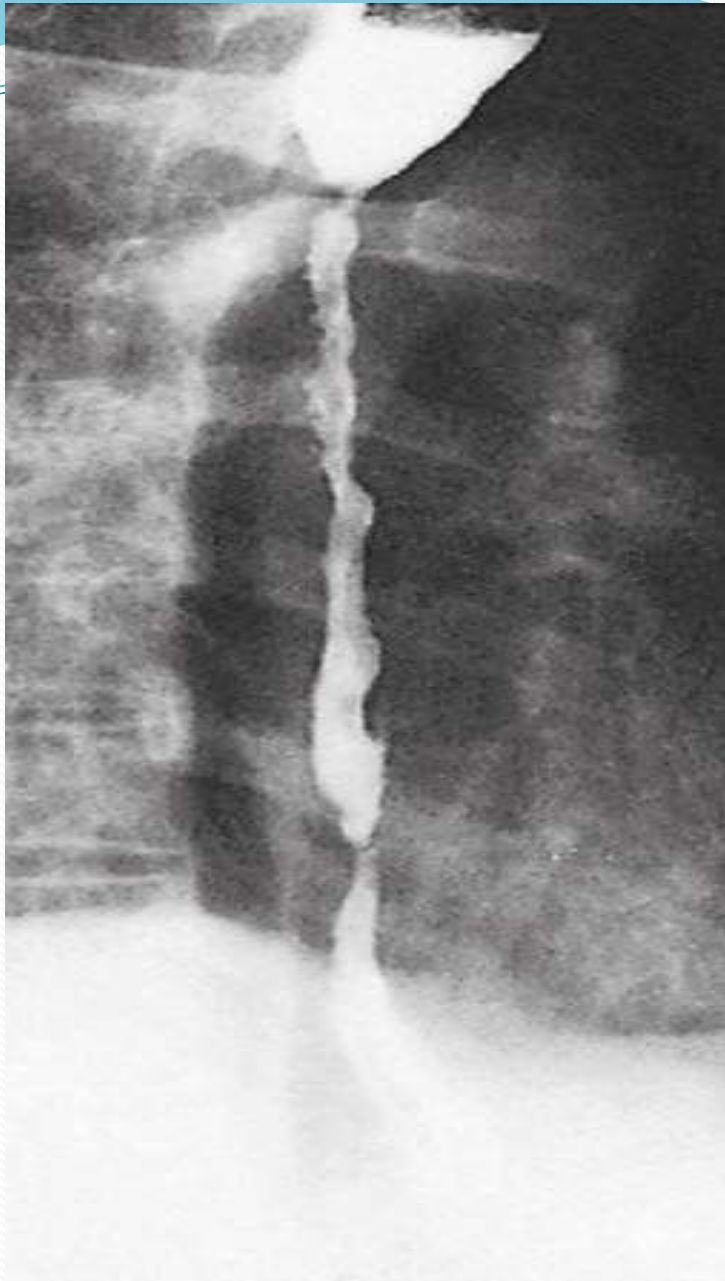


CORROSIVE INJURY

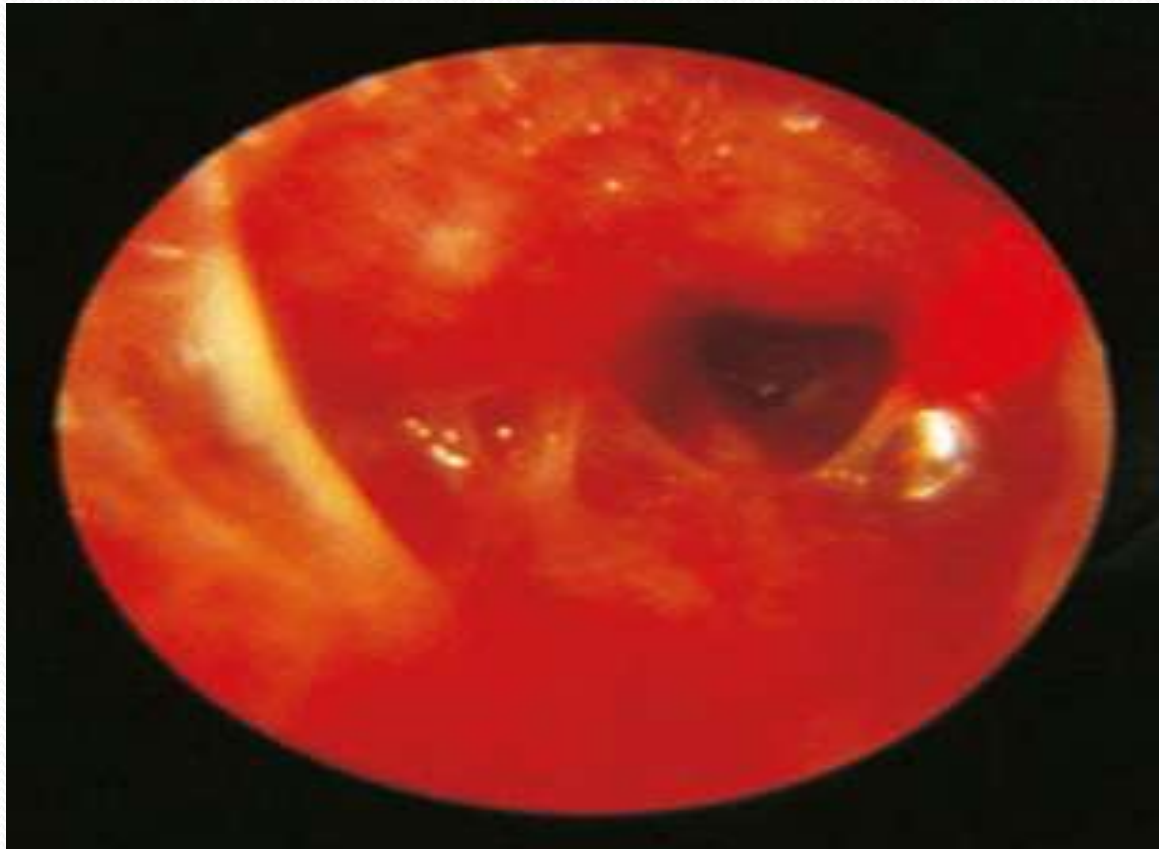
CORROSIVE INJURY

Accidental ingestion occurs in children and when corrosives are stored in bottles labelled as beverages. All can cause severe damage to the mouth, pharynx, larynx, oesophagus and stomach. *The type of agent, its concentration and the volume ingested largely determine the extent of damage.* In general, alkalis are relatively odourless and tasteless, making them more likely to be ingested in large volume

Alkalis cause liquefaction, saponification of fats, dehydration and thrombosis of blood vessels that usually leads to fibrous scarring. **Acids** cause coagulative necrosis with eschar formation, and this coagulant may limit penetration to deeper layers of the oesophageal wall. *Acids also cause more gastric damage than alkalis because of the induction of intense pylorospasm with pooling in the antrum.*



Caustic or lye stricture with marked stenosis high in the body of the oesophagus.



Acute caustic burn in the haemorrhagic phase

DRUG-INDUCED INJURY

Many medications, such as antibiotics and potassium preparations, are potentially damaging to the oesophagus, as tablets may remain for a long time, especially if taken without an adequate drink.

Acute injury presents with dysphagia and odynophagia, which may be severe. The inflammation usually resolves within 2–3 weeks, and no specific treatment is required apart from appropriate nutritional support.

A stricture may follow